

ALLOWRAP CLINICAL REPORT SERIES

VOLUME 1

REVISIONAL TARSAI TUNNEL DECOMPRESSION WITH ALLOWRAP® DS

Matthew D. Hinderland, DPM¹, Alan Ng, DPM, FACFAS²

Address correspondence to: Alan Ng, DPM, FACFAS, Highlands-Presbyterian St. Luke's Podiatric Medicine and Surgery Program, Presbyterian St. Luke's Medical Center.
Contact: ang@advancedortho.org. 303-344-9090. 8101 E. Lowry Blvd, Suite 230, Denver, CO 80230

1. Highlands-Presbyterian St. Luke's Podiatric Residency Program, Presbyterian St. Luke's Medical Center, Denver, CO.

2. Advanced Orthopedic and Sports Medicine Specialists, Denver, CO, Highlands-Presbyterian St. Luke's Podiatric Medicine and Surgery Program, Presbyterian St. Luke's Medical Center Denver, CO.

Financial Disclosure: The authors have received financial compensation from AlloSource® for preparation of this case report.

ABSTRACT

Tarsal tunnel revision surgery has significantly worse outcomes than primary tarsal tunnel decompressions. One of the reasons for failed initial tarsal tunnel decompression is excessive external scarring around the nerve. We present a case of revisional tarsal tunnel decompression where the initial failure was thought to be from excessive external scarring. At five month follow-up after the revision surgery, the patient had complete resolution of symptoms with the use of AlloWrap DS.

Introduction

Tarsal Tunnel Syndrome (TTS) is an entrapment neuropathy of the tibial nerve at the tarsal tunnel. The cause of TTS may be intrinsic or extrinsic compression of the tibial nerve. Bony deformity caused by the fracture of talus or calcaneus, post-traumatic fibrosis, hypertrophy of the abductor hallucis, hindfoot valgus deformity, ganglion cyst, talocalcaneal coalition, varicosities, lipomas, neurilemmomas, and synovitis have all been reported as causes of TTS.¹ Clinical history and physical examination are typically more helpful than electrodiagnostic studies in determining the extent and location of the tibial nerve irritation following previous tarsal tunnel decompression surgery.²

Reasons for failure of an initial tarsal tunnel decompression include: inadequate release due to a lack of understanding of the anatomy involved, failure to execute the release properly, bleeding with subsequent scarring, damage to the nerve or its branches in the course of the release, persistent hypersensitivity of the irritated nerve, and intrinsic damage to the nerve initially.³

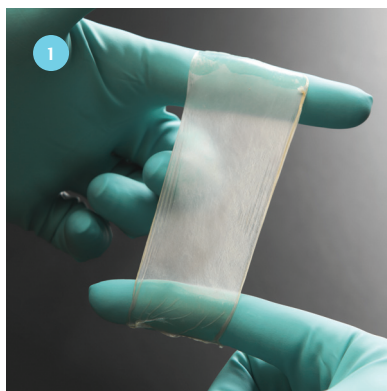


Figure 1. AlloWrap DS

Failed TTS surgeries are better prevented than treated, because outcomes for revision procedures are significantly worse than for primary procedures.⁴ Treatment of the scarred nerve frequently yields unpredictable results. The tibial nerve elongates an average of 5.9mm in hyperpronating feet and an average of 3.4mm even when pronation is controlled.⁵ Neurolysis may be of temporary benefit, but recurrent scarring leads to return of the neuropathic pain. The pain from extraneural scarring may result from several different mechanisms: impairment of epineural blood flow leading to nerve ischemia, circumferential scarring causing a mechanical constriction of the nerve, and adhesions prohibiting gliding of the nerve.⁶

We present a case of revisional tarsal tunnel decompression where the initial failure was thought to be from excessive external scarring. The patient had complete resolution of symptoms after the revision surgery with the use of AlloWrap DS (Figure 1).

Case Presentation

A 61 year old female presented with radiating pain from the left posterior-medial ankle that extended along her plantar foot to all five toes. The pain was worse with weight bearing and orthotics offered no relief of the symptoms. On physical exam, the patient had a positive Tinel's sign over the tibial nerve. There was no palpable mass over the tarsal tunnel. The radiating pain could also be worsened by placing a valgus stress on the rearfoot.

Her past medical history was significant for anxiety, for which she took Lorazepam. Past surgical history included an open plantar fasciotomy performed on the same foot two years earlier. The patient had no known drug allergies and denied tobacco, alcohol, and illicit drug use.

The patient had a MRI that was positive for a space occupying lesion in the tarsal tunnel. The MRI was read as a likely ganglion cyst, originating from the tendon sheath of the flexor hallucis longus tendon. She also had electromyography and a nerve conduction study performed that was positive for TTS.

The patient underwent an open tarsal tunnel decompression with excision of the ganglion cyst, which appeared to originate from the flexor hallucis longus tendon. The lacinate ligament was completely released and the medial and lateral plantar nerves were released distally by opening the porta pedis. The medial calcaneal nerve was also identified and released distally. The entire decompression was performed under loupe magnification. The deep layers were left open and only the skin was closed. The patient was non-weight bearing for two weeks and then progressed to full weight bearing over the next two weeks. The patient was placed on Pregabalin post-operatively for three months, and started physical therapy at five weeks post-operatively. Ten weeks after the surgery, the patient began having increasing symptoms consistent with recurrent TTS. She was found to have a thickened, immobile cicatrix over the surgical incision, and the patient was sent back to physical therapy for manual mobilization of the scar tissue. The patient continued to have paresthesias radiating distally from her tarsal tunnel and a positive Tinel's sign over her tibial nerve for the next six months after the initial surgery. She had a repeat MRI six months post-operatively that showed no recurrence of the soft tissue mass and no space occupying lesion. The patient also had repeat electromyography and nerve conduction studies that were normal. The patient had a diagnostic and therapeutic kenalog and local anesthetic injection in the tarsal tunnel seven months after the initial surgery to see if it would provide relief. This injection provided temporary pain relief, but her symptoms recurred within one week. It was therefore recommended the patient have a repeat tarsal tunnel decompression, and AlloWrap DS be used around the tibial nerve to provide a protective barrier.

The patient underwent a revision tarsal tunnel decompression eight months after the initial operation. After all scar tissue had been excised and a complete tarsal tunnel decompression had been performed, as described earlier, AlloWrap DS was trimmed to the appropriate length and placed around the tibial nerve circumferentially (*Figure 2*). The tissue was then secured with a 6.0 monocryl running suture with care taken to not pass the needle through the nerve itself (*Figure 3*). Two additional smaller pieces of AlloWrap DS were placed around the medial and lateral plantar nerve branches, respectively, and secured in a similar fashion.

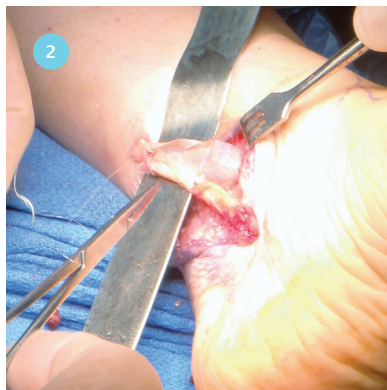


Figure 2. AlloWrap DS being placed around the tibial nerve.

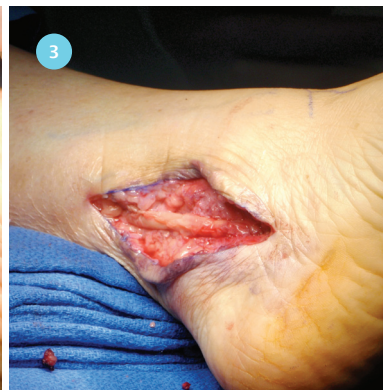

Figure 3. Final picture of tibial nerve wrapped with AlloWrap DS with monocryl sutures in place.

Post-operatively, the patient was non-weight bearing for two weeks, and the patient started physical therapy at three weeks. The patient had complete resolution of the paresthesias on her first post-operative visit, which continued through the most recent follow-up five months later. Subjectively, post-operative results using AlloWrap DS tissue were much improved as compared to the previous procedure.

Discussion

Barrier wrapping is a technique that is commonly used to prevent external scarring of nerves and adherence to adjacent tissue. The barrier would ideally be inert so as to not incite an inflammatory response. It would also be a substance that decreases nerve scarring, does not constrict and thus compress the nerve, and improves nerve gliding.⁷ Traction neuritis and pain typically results if external scarring occurs around a nerve. Nerves are frequently surrounded by loose adipose tissue in the natural state. Many different substances have been used to surround nerves such as fat, fascia, collagen, gelatin, decalcified bone, blood vessels, cartilage, muscle, polyglactin, rubber, silicone tubing, and silastic sheeting.⁶ However, many of these materials block nerve neovascularization and cause edema and fibrosis. A recent report on allograft and autograft vein wrappings for scarred nerves yielded 79.6% good or excellent results.⁶ However, allograft veins were associated with an increased risk of infection. Intraneural scarring was also associated with a higher rate of failure. Barker et al. reported on 44 patients who had revision tarsal tunnel surgery without barrier wrapping.⁸ Their results in terms of patient satisfaction showed that 22% of patients had fair or poor results. Another study on tarsal tunnel revision surgery showed that patients with encasement of the tibial nerve in scar tissue and an adequate distal release at the previous tarsal tunnel surgery did poorly overall.²

AlloWrap DS is a human amniotic membrane designed to provide a biologic barrier following surgical repair. AlloWrap DS is a double-sided membrane with two layers of amniotic tissue oriented with the epithelial layers facing outwards. The tissue is packaged wet, as opposed to several other products, so no rehydration is required. It provides a thin, strong membrane that conforms around tissues and may be positioned with or without suturing. Clinically, the tissue is immune privileged, and remains in the surgical site greater than eight weeks.^{9,10} AlloWrap DS has several advantages over autograft tissue, including its availability in various diameters and quantities and the avoidance of donor site morbidity and scarring.

Human amniotic tissue has been used in different surgical procedures to prevent adhesions and minimize inflammation during the initial post-operative period. In both ovine and canine spinal laminectomy models, human amniotic membranes were found to decrease adhesions to the underlying dura.^{10,11} In 2011, Meng investigated the use of human amniotic membranes to wrap sciatic nerves in a rat model and found that the membrane decreased adhesions and scar formation. He hypothesized that the lack of adhesions may help the nerve retain its mobility and therefore prevent traction injury and ischemia.¹² In 2002, Demirkan evaluated the use of amniotic membranes in flexor tendons repairs and found significantly reduced amounts of adhesions. He also found three months after the repair, no remnants of the amniotic membrane were present at the tendon repair site.¹³

In this clinical series using AlloWrap DS tissue, we have found our clinical results to be consistent with previous studies. We attribute the improved surgical outcome to the ability of AlloWrap DS to form a tissue layer around the nerve and protect the tibial nerve from the surrounding soft tissue. AlloWrap DS allows the nerve to glide freely and allows physiologic elongation of the nerve in the initial post-operative period.

References

1. Fujita I, Matsumoto K, Minami T, Kizaki T, Akisue T, Yamamoto T. Tarsal tunnel syndrome caused by epineural ganglion of the posterior tibial nerve: report of 2 cases and review of the literature. *J Foot Ankle Surg.* 2004;43(3):185-90.
2. Skalley TC, Schon LC, Hinton RY, Myerson MS. Clinical results following revision tibial nerve release. *Foot Ankle Int.* 1994;15(7):360-7.
3. Gould JS. The failed tarsal tunnel release. *Foot Ankle Clin.* 2011;16(2):287-93.
4. Raikin SM, Minnich JM. Failed tarsal tunnel syndrome surgery. *Foot Ankle Clin.* 2003;8(1):159-74.
5. Graham ME, Jawrani NT, Goel VK. Effect of extra-osseous talotarsal stabilization on posterior tibial nerve strain in hyperpronating feet: a cadaveric evaluation. *J Foot Ankle Surg.* 2011;50(6):672-5.
6. Masear VR. Nerve wrapping. *Foot Ankle Clin.* 2011;16(2):327-37.
7. Sarris IK, Sotereanos DG. Vein wrapping with autologous graft for recalcitrant median nerve compression. *Atlas Hand Clin.* 2002;7:287-9.
8. Barker AR, Rosson GD, Dellon AL. Outcome of neurolysis for failed tarsal tunnel surgery. *J Reconstr Microsurg.* 2008;24(2):111-8.
9. Akle CA, Adinolfi M, Welsh KI. Immunogenicity of human amniotic epithelial cells after transplantation into volunteers. *Lancet.* 1981;2:1002-5.
10. Samaniego AC, Ronholdt CJ, Ryan S, Ehrhart EJ, et al. Human amniotic tissue as an anti-adhesion, anti-inflammatory barrier in an ovine spinal laminectomy model. 2009; AlloSource.
11. Tao H, Fan H. Implantation of amniotic membrane to reduce postlaminectomy epidural adhesions. *Eur Spine J.* 2009;18(8):1202-12.
12. Meng H, Li M, You F, Du J, Luo Z. Assessment of processed human amniotic membrane as a protective barrier in rat model of sciatic nerve injury. *Neuroscience Letters.* 2011;496:48-53.
13. Demirkan F, Colakoglu N, Herek O, Erkula G. The use of amniotic membrane in flexor tendon repair: an experimental model. *Arch Orthop Trauma Surg.* 2002;122:396-9.



6278 S Troy Cir, Centennial, CO 80111

MAIN 720. 873. 0213 TOLL FREE 800. 557. 3587 FAX 720. 873. 0212 allosource.org