

ALLOWRAP CLINICAL REPORT SERIES

VOLUME 4 - CASE STUDY

CLINICAL EXPERIENCE WITH ALLOWRAP® DS AMNIOTIC MEMBRANE USED AS A BARRIER TO MINIMIZE ADHESIONS FOLLOWING SPINAL SURGERY

Jan Duncan, M.D.

Orthopedic Spine Surgeon, California Spine

ABSTRACT

Failed Back Surgery Syndrome (FBSS) is a loosely defined disorder characterized by intractable pain and varying degrees of functional incapacity following lumbar spine surgery that often requires reoperation. FBSS is frequently triggered by epidural fibrosis,^{2,3} a very common and normal result of even successful surgical intervention.² Prevention of epidural fibrosis could lead to fewer cases of FBSS and to a significant extent, reduce complications during reoperation procedures.

The implantation of a mechanical barrier between the dura mater and overlying tissue can reduce epidural fibrosis and scar adhesions. Various materials, including silastic, synthetic membranes and free fat or pedicle fat grafts, have been used in an attempt to reduce scar formation, but none of them have yielded consistent results.^{1,2,3,4}

Amniotic membrane (AM), the inner layer of the fetal membrane, has been used in experimental trials for many purposes, including reducing surgical adhesions. In addition to serving as a mechanical barrier, AM also may reduce postoperative adhesions by chemically inhibiting inflammation, which can reduce vascularization and fibrosis.^{1,3,6,8} Further, AM is an immune privileged tissue so it will not cause an immunologic reaction.^{15,16,17, 8,19,20}

We present three patient cases in which a layer of amniotic membrane, AlloWrap® DS (AlloSource®, Centennial, CO), was implanted between the dura mater and the overlying paraspinal muscles during a fusion procedure in an attempt to limit the formation of epidural fibrosis and scar adhesions. During subsequent reoperation for pseudoarthrosis, none of the patients exhibited adhesions or dural leaks and tissue easily peeled away from the dura. Furthermore, histological evaluation of the tissue suggested the presence of scar tissue, but none on the side facing the dura.

Introduction

Various biological and synthetic materials have been used with limited success to prevent postlaminectomy epidural adhesions. These barrier materials include hemostatic sponges^{1,3}, free fat grafts^{1,3,5,6,21,23}, silastic, hyaluronic acid, polyactic acid^{22,23}, carboxymethylcellulose gels²⁴, a mixture of dextran sulfate and gelatin (Adcon-L, Adba)^{1,3,6,21,23}, 5-fluorouracil, cyclosporine and radiation therapy.

To be effective, such barriers must remain in place through the proliferation phase of the healing process and into the remodeling phase. During the proliferation phase, new cells are produced to close the wound, but the cells contract as they mature, causing adhesions. Remodeling requires the fibroblast matrix, or scar, to mature to replace the lost tissue. The process of scar remodeling is responsible for the final aggregation, orientation and arrangement of collagen fibers. This process continues until the remodeling phase ends at six months to a year post injury.¹⁵

Amniotic membrane (AM) has been used experimentally to reduce surgical adhesions in abdominal^{7,8}, ophthalmic^{9,10} and spine surgery.^{1,12,13,14} It is the only surgical barrier that has been shown to remain in the body as the healing process extends into the remodeling phase.¹⁵

In addition to serving as a mechanical barrier, AM modulates levels of cytokine and growth factor activity to enhance antifibroblastic and antibacterial effects.^{6,8,25,26,27} The membrane also contains a host of growth factors that promote wound healing and suppress inflammation and neovascularization, including epidermal growth factor, hepatocyte growth factor, nerve growth factor, anti-inflammatory cytokines (interleukin-6) and anti-vasculogenic factors (thrombospondin and tissue inhibitors of metalloproteases).⁶ Moreover, AM does not express HLA-A, B, C or DR antigen or beta-2 microglobulin, helping to ensure an immunological reaction after implantation does not occur.^{6,15}

AlloWrap® DS (AlloSource®, Centennial, CO) is an amniotic membrane graft obtained from donated human placenta following elective C-section deliveries. The product is double-sided, with two layers of amniotic tissue oriented with the epithelial layers facing outward. AlloWrap is available moist or dehydrated and can be stored at room temperature for immediate use. AlloWrap can effectively be positioned with or without suturing.

Case Presentation

Patient 1 is a 65 year old female diagnosed with scoliosis and spinal stenosis. In August 2012, she underwent an interbody fusion, bilateral posterolateral fusion, bilateral laminectomy and foraminotomy procedure (L1-5S1), at which time two AlloWrap DS grafts, sized 2 x 4 cm and 2 x 2 cm, were implanted between the dura mater and the overlying paraspinal muscles. A follow-up surgery was performed 15 months later for a nonunion.

Patient 2 is a 55 year old female diagnosed with degenerative disk disease and foraminal stenosis. In March 2013, this patient underwent a bilateral posterolateral fusion and bilateral laminectomy and foraminotomy (L4-5S1), at which time one 4 x 4 cm AlloWrap DS graft was implanted between the dura mater and the overlying paraspinal muscles. A follow-up surgery was performed eight months later for a nonunion.

Patient 3 is a 46 year old man diagnosed with degenerative disk disease, had a bilateral posterolateral fusion and bilateral laminectomy and foraminotomy performed, and then had a 2 x 4 AlloWrap DS graft implanted on the dura. A follow-up surgery was performed two years later for a nonunion.

Results

The surgical site was assessed during the course of all three follow-up procedures and the AlloWrap DS grafts were removed from the first two patients and sent to a pathologist for microscopic analysis to examine the degree of epidural fibrosis. In the third patient, no tissue was available to send back.

An evaluation of the presence of adhesion and the quality of the dissection plane occurred during the follow-up procedures. All patients had easily detachable and separable tissues at the site of the original placement of the AlloWrap DS with light use of common blunt surgical instruments. Further, there were no adhesions or dural leaks (*Figure 1*).

In addition to manual manipulation, microscopic analyses revealed that scar tissue was present but had not adhered to the dura at eight months (*Figure 2*). After one year, the scar tissue had adhered more noticeably to the membrane, but only on the side facing away from the dura (*Figure 3*). The third patient had the longest duration between surgeries and no AlloWrap DS remnants could be sent in for histology for analysis.

A review of all patients' medical charts indicated there were no complications due to the placement of the AlloWrap DS.

Discussion

Clearly, implantation of an optimal mechanical barrier between the dura mater and overlying tissue can reduce epidural fibrosis and scar adhesions. Ideally the barrier should remain in place well into the healing process and not readily adhere to the overlying tissue. These criteria were clearly met in these two cases using AlloWrap DS.

While the success of these three cases cannot guarantee equally positive results in others, the implantation of AlloWrap DS in these instances significantly reduced epidural fibrosis based on microscopic and direct evaluation. Additional benefits that should be studied further are reduction in FBSS, reduced operating room time during reoperations and reduced complication rates associated with simpler dissections during reoperation procedures.

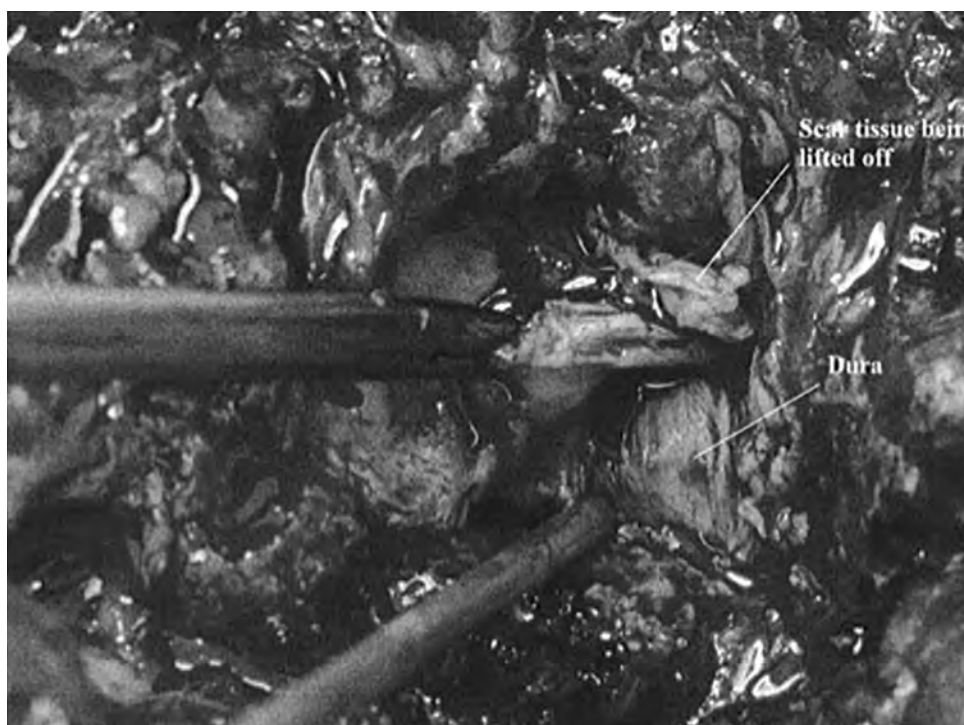


Figure 1. Scar tissue being lifted off the dura.

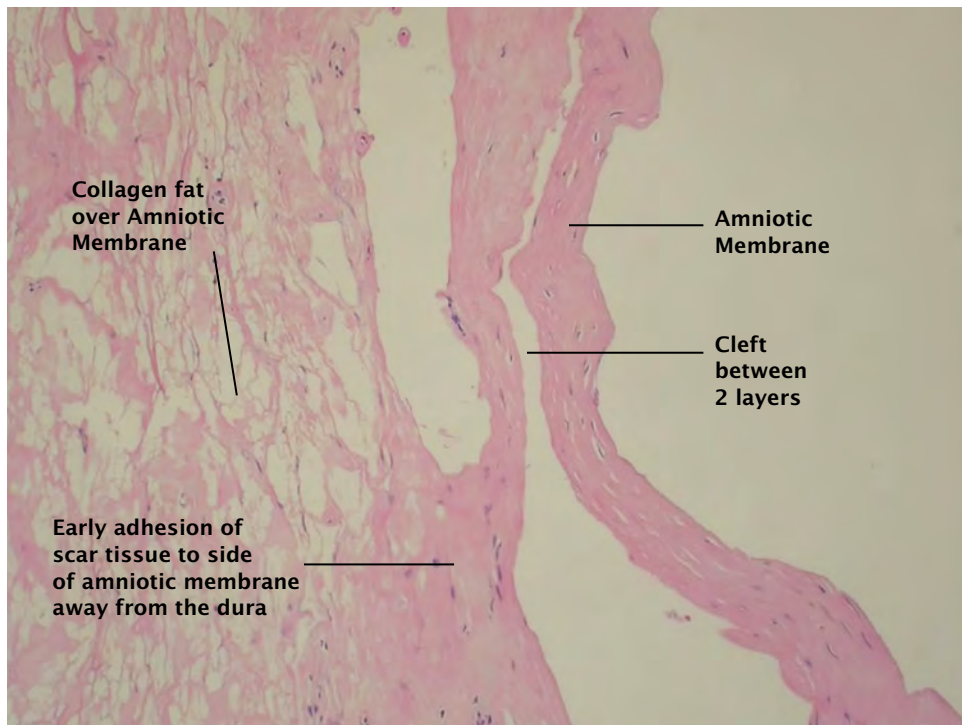


Figure 2. Eight months follow-up pathology slide.

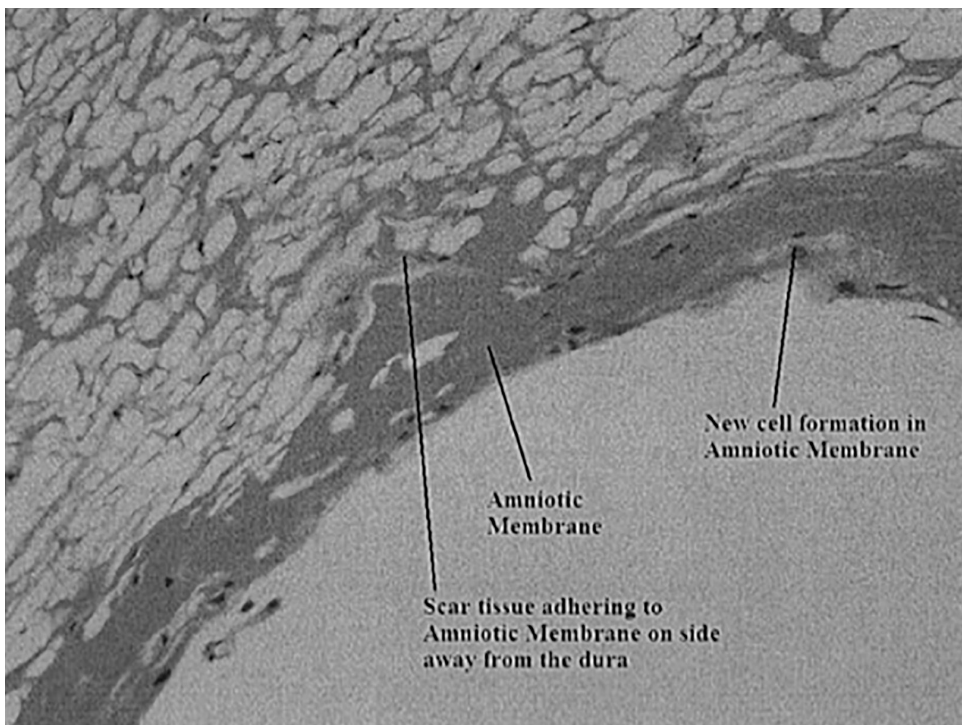


Figure 3. Fifteen months follow-up pathology slide.

References

1. Tao H, Fan H. Implantation of amniotic membrane to reduce postlaminectomy epidural adhesions. *Eur Spine J* 2009.
2. Bosscher HA, Heavner JE. Incidence and severity of epidural fibrosis after back surgery: an endoscopic study. *Pain Pract* 2009; 10:18-24.
3. Choi HJ, Kim KB, Kwon YM. Effect of amniotic membrane to reduce postlaminectomy epidural adhesion on a rat model. *J Korean Neurosurg Soc* 2011;49:323-328.
4. Ross JS, Robertson JT, Frederickson RC, et al. Association between peridural scar and recurrent radicular pain after lumbar discectomy: magnetic resonance evaluation. *Rapid Communication* 1996;38:855-863.
5. Xuan-he S, CHang-dong F, Yao Li. Effect of double-layer human amnion on wound healing in deep second-degree burns of animals. *Journal of Clinical Rehabilitative Tissue Engineering Research* 2008;12:5389-5392.
6. Mamede AC, Carvalho MJ, Abrantes AM, Laranjo M, Maia CJ, Botelho MF. Amniotic membrane: from structure and functions to clinical applications. *Cell Tissue Res* 2012.
7. Fetterwolf DE, Snyder RJ. Scientific and clinical support for the use of dehydrated amniotic membrane in wound management. *Wounds* 2012;24:299-307.
8. John T. Human amniotic membrane transplantation: past, present, and future. *Ophthalmol Clin N Am* 2003;16:43-65.
9. Mason SL, Stewart RMK, Keams VR, Williams RL, Sheridan CM. Ocular epithelial transplantation: current uses and future potential. *Regen Med* 2011;6:767-782.
10. Dua HS, Azuara-Blanco A. Amniotic membrane transplantation. *Br J Ophthalmol* 1999;83 :748-752.
11. Samaniego A. Human Amniotic Tissue as an Anti-adhesion, Anti-fibrotic barrier in an ovine spinal laminectomy model. *AlloSource White Paper* 2011.
12. Tomita T, Hayashi N, Okabe M, et al. New dried human amniotic membrane is useful as a substitute for dural repair after skull base surgery. *J Neuro Surg B* 2012;73:302-307.
13. Kudriashov AF, Artarian AA, Putsillo MV. Use of amnion to repair a dural defect. *Zhurnal Voprosy Neurokhirurgii Imeni N. N. Burdenko* 1981;5:37-40.
14. Chao Y, Humphreys S, Penfield W. A new method of preventing adhesions: the use of amnioplastin after craniotomy. *BMJ* 1940:517-520.
15. Samaniego A. AlloWrap surgical barrier remains in the body through the cell proliferation phase of the healing process while other surgical barriers are resorbed. *AlloSource White Paper* 2011.
16. Hasegawa M, Fujisawa H, Hayashi Y, Yamashita J. Autologous amnion graft for repair of myelomeningocele: technical note and clinical implication. *J Clin Neurosci* 2003;11:408-411.
17. Streilein JW. Unraveling Immune Privilege. *Science* 1995;270:1158-1159.
18. Aide CA, Welsh KI, Adinolfi M, Leibowitz S, McColl I. Immunogenicity of human amniotic epithelial cells after transplantation into volunteers. *The Lancet* 1981: 1003-1005.
19. Bourne G. The Foetal Membranes: A review of normal amnion and chorion and some aspects of their function. *Postgrad Med J* 1962;38:193-201.
20. Saal JS, Franson RC, Dobrow R, Saal JA, White AH, Goldthwaite N. High levels of inflammatory phospholipase A2 activity in lumbar disc herniations. *Spine* 1990.

21. Zacharious Z. Amniotic Membranes as prosthetic material: Experiment utilization data of a rat model. Elsevier 1997;32:1458-1463.
22. Demirkan F, Colakoglu N, Herek O, Erkula G. The use of amniotic membrane in flexor tendon repair: an experimental model. Arch Orthop Trauma Surg 2002;122:396-399.
23. Kim SS, Sohn SK, Lee KY, Lee MJ, Roh MS, Kim CH. Use of human amniotic membrane wrap in reducing perineural adhesions in a rabbit model of ulnar nerve neuropathy. J Hand Surg 2009;0:1-6.
24. Meng H, LiM, You F, Du J, Zhuojing L. Assessment of processed human amniotic membrane as a protective barrier in rat model of sciatic nerve injury. Neuroscience Letters 2011;496:48-53.
25. Fujisato T, Tomihata K, Tabata Y, Iwamoto Y, Burczak K, Ikada Y. Cross-linking of amniotic membranes. J Biomater Sci Polymer Edn 1999;10:1171-1181.
26. Spoerl E, Wollensak G, Reber F, Pillunat Lutz. Cross-linking of human amniotic membrane by glutaraldehyde. Ophthalmic Res 2004;36:71-77.
27. Toda A, Okabe M, Yoshida T, Nikaido T. The potential of amniotic membrane/amnion derived cells for regeneration of various tissues. J Pharmacol Sci 2007;105:215-228.



Dr. Jan Duncan, California Spine's respected and talented surgeon, has a long and distinguished career as a physician and pioneering orthopedic surgeon. Dr. Duncan has helped develop the field of orthopedics and continues to contribute through research and presenting at conferences and seminars. With an ongoing commitment to helping his patients find solutions to back pain, conditions and injuries, Dr. Duncan continues to lead in the field of orthopedic surgery.

Jan Duncan, M.D.

ALLOWRAP® CLINICAL REPORT SERIES

VOLUME 4 - CASE STUDY



6278 S Troy Cir, Centennial, CO 80111, USA

MAIN 720. 873. 0213 TOLL FREE 800. 557. 3587 FAX 720. 873. 0212 allosource.org